

See discussions, stats, and author profiles for this publication at: <https://www.researchgate.net/publication/47393385>

# Restoring endodontically treated teeth with all-ceramic endo-crowns: Case report

Article in *Stomatoloski glasnik Srbije* · January 2008

DOI: 10.2298/SGS0801054V · Source: DOAJ

CITATIONS

48

READS

4,974

4 authors, including:



**Valentina Veselinović**  
University of Banja Luka

25 PUBLICATIONS 63 CITATIONS

SEE PROFILE



**Aleksandar Todorović**  
University of Belgrade

40 PUBLICATIONS 347 CITATIONS

SEE PROFILE



**Vojkan Lazic**  
University of Belgrade

76 PUBLICATIONS 393 CITATIONS

SEE PROFILE

Some of the authors of this publication are also working on these related projects:



ATLAS OF IMPLANT DENTISTRY AND TOOTH PRESERVING SURGERY. PREVENTION AND MANAGEMENT OF COMPLICATIONS [View project](#)



Optoelectronic nanodimensional systems-path to implementation [View project](#)

# Primena bezmetalnih endokruga u protetskoj terapiji endodontski lečenih zuba – prikaz slučaja

DOI: 10.2298/SGS0801054V

## Restoring endodontically treated teeth with all-ceramic endo-crowns– case report

Veselinović Valentina<sup>1</sup>, Todorović Aleksandar<sup>2</sup>, Lisjak Dejan<sup>3</sup>, Lazić Vojkan<sup>2</sup>

1. Medicinski fakultet Banja Luka, Odsjek stomatologija
2. Klinika za stomatološku protetiku, Stomatološki fakultet Beograd
3. Privatna stomatološka ordinacija „Primarijus Dr Đuro Lisjak“, Beograd

1. School of Medicine, Dept of Dentistry, Banja Luka
2. Dept of prosthetic dentistry, School of Dentistry, Belgrade
3. Dental office „Prim dr. Đuro Lisjak“, Belgrade

### PRIKAZ IZ PRAKSE (PP) CASE REPORT

#### KRATAK SADRŽAJ

Bezmetalne endokrone su jednokomadne nadoknade koje se koriste u terapiji endodontski lečenih zuba u uslovima smanjene vertikalne dimenzije krunice zuba.

**Cilj** ovog rada je bio da se na slučajevima iz kliničke prakse predstave dve tehnike izrade endokruga i da se poređenjem karakteristika tih sistema ukaže na njihove prednosti i nedostatke.

Kod jednog pacijenta, za izradu endokruga korišćena je jednoseansna izrada Cerec CAD-CAM sistemom, a kod drugog presovanje keramike Empres II sistemom.

Obe tehnike, i Cerec CAD – CAM i Empress II sistem, pokazale su podjednako dobre rezultate, u smislu funkcionalnosti, retencije, estetike i dugotrajnosti endokruga. Osnovna razlika je u trajanju procedure izrade endokruga jer Cerec CAD – CAM sistem omogućava tretman u samo jednoj poseti pacijenta i koristi širu paletu gradivnih materijala..

**Ključne reči:** Endodontski lečeni zubi, endokruna, Cerec, Empress II

#### SUMMARY

The all-ceramic endocrowns are one piece restoration used in the therapy of endodontically treated teeth, usually, with a decreased vertical dimension of the tooth crown.

The **aim** of this paper is to describe two techniques of the making of endocrowns using case studies and to present the advantages and disadvantages of both techniques by way of their comparison.

Chair-side production with the Cerec CAD-CAM system and pressing of the ceramic with the Empres II system was used for the production of the endocrowns.

Cerec CAD-CAM and Empres II systems yielded equally good results in the production of the endocrowns, in terms of their functionality, retention, aesthetic and duration. The basic difference between them is the length of the endocrown production procedure as the Cerec CAD-CAM system makes it possible to apply the treatment during a single visit using a wide range of materials...

**Key words:** endodontically treated teeth, endocrown, Cerec, Empress II

## Uvod

Rehabilitacija endodontski zbrinutih zuba je stalno prisutan problem rekonstruktivne stomatologije. U uslovima kada preostala zdrava zubna tkiva ne pružaju potrebnu retenciju konvencionalnim ispunima, terapija može biti sprovedena na više načina. „Zlatni standard“, na našem podneblju, još uvek predstavlja laboratorijski izrađena metalna nadogradnja. Međutim, o ovoj terapiji postoje različita mišljenja, u naučnim i stručnim krugovima<sup>1,2</sup>.

Konfekcijski kočići, različitih oblika i materijala, predstavljaju savremenu alternativu livenoj nadogradnji. Kod metalnih kočića je klinička praksa ukazala na probleme u vidu gubitka kočića usled frakture zuba ili rascementiranja<sup>3</sup>. Takvi korenski kočići služe isključivo retenciji koronarne restauracije, ali ne i za stabilizaciju korena<sup>4</sup>. Štaviše, kliničkim praćenjem, dokazane su češće frakture korena u odnosu na druge vidove protetske terapije devitalizovanih zuba<sup>5,6</sup>.

Razvojem adhezivnih sistema i bezmetalnih keramičkih nadoknada javila se potreba za uvođenjem novih oblika kočića. U široku upotrebu su ušli estetski kočići (vlaknima ojačani kompozitni kočići i yttrium stabilizovani cirkon-oksidi kočići)<sup>7</sup>. Klinička iskustva su dala prednost ojačanim kompozitnim kočićima, zbog relativno jednostavnog uklanjanja u slučaju potrebe za revizijom i zbog modula elastičnosti sličnog dentinu zuba<sup>8</sup>. Sve sile se prenose na celu dužinu kočića, čime se smanjuje mogućnost frakture korena zuba.

Verovatno najveći problem u protetskoj rehabilitaciji endodontski lečenih zuba predstavlja nedostatak interokluzionog prostora za izradu zubne nadoknade. U praksi su se nametala različita rešenja. Tako se pre više decenija pojavila tzv. Richmond krunica, odnosno krunica koja je imala metalnu strukturu dobijenu jednodielnim livenjem korenskog i krunicnog dela u vidu kape ili postolja<sup>9</sup>. Rešenje je naizgled bilo pronađeno, ali je zbog komplikovanog odnosno veoma često i neizvodljivog uklanjanja, relativno brzo napušteno. Ostala je samo ideja vodilja o jednodielnim nadoknadama, za budući razvoj gradivnih materijala i tehnologija.

Razvoj novih keramičkih materijala, a pogotovu dentalnih CAD-CAM (kompjuterom kontrolisano dizajniranje i izrada) sistema, je revitalizovao mogućnost izrade jednodielnih nadoknada, bezmetalnih endokruna, karakterisanih visokom biokompatibilnošću i dobrim mehaničkim osobinama. One se danas definišu kao jednodielne nadoknade, koja se sastoje od dela koji odgovara obrađenom kanalu korena i morfološki oblikovanog krunicnog dela. Za njihovu izradu savremena stomatologija nudi čitavu paletu različitih mogućnosti.

Cilj ovog rada je bio da se predstavje dve tehnike izrade endokruna na primerima iz kliničke prakse, te da se poređenjem karakteristika tih sistema ukaže na njihove prednosti i nedostatke.

## Introduction

The rehabilitation of endodontically treated teeth is a constant problem in reconstructive dentistry. When the remaining dental tissues do not provide sufficient retention for conventional restorations, the treatment may be carried out in several ways. "The golden standard" in our country is still the laboratory fabrication of metal restorations. However, there are different opinions on this type of treatment in scientific and professional circles.<sup>1,2</sup>

Pre-fabricated posts, different in shape and material, are a contemporary alternative of cast posts. Clinical experience has revealed certain problems with metal posts, such as tooth fracture or debonding.<sup>3</sup> Such root canal posts are designed for the retention of the crown restoration but not for root stabilization.<sup>4</sup> Moreover, there has been clinical evidence of more frequent root fractures in these cases compared to other types of prosthodontic reconstruction of pulpless teeth.<sup>5,6</sup>

With the development of adhesive systems and all-ceramic restorations, the need for new types of posts has emerged. Aesthetic posts have become widespread (fibre-reinforced composite posts and yttrium-stabilized zirconium-oxide posts).<sup>7</sup> Clinical experience has given favour to reinforced composite posts due to the relative ease of post removal when re-treatment is indicated and modulus of elasticity similar to dentine.<sup>8</sup> All forces are transferred to the entire post length reducing the risk for root fracture.

Probably the biggest problem in the prosthodontic rehabilitation of endodontically treated teeth is the insufficient inter-occlusal space for a tooth restoration. There have been different solutions in the clinical practice. The so-called Richmond crown was introduced several decades ago with a single-unit metal structure produced by casting the root and crown parts in a cap- or stand-shape.<sup>9</sup> The solution was seemingly found but was abandoned relatively quickly due to the complicated and often impossible removal. Only the idea of single-unit restorations was kept, for future development of restorative materials and technologies.

The development of ceramic materials, and especially dental CAD-CAM (computer-aided design and manufacturing) systems revitalized the possibility to produce single-unit restorations, all-ceramic endo-crowns, characterized by high biocompatibility and good mechanical properties. Today, these are defined as single-unit restorations, corresponding to the prepared canal and morphologically shaped crown. Modern dentistry offers a wide range of different solutions for the production of these restorations.

The aim of this paper was to present case studies of two techniques for producing endo-crowns and discuss advantages and disadvantages of both.

## Subjekti i metode

U radu su, kroz primere iz prakse, prikazane dve tehnike izrade bezmetalnih endokruna: jednoseansna - CEREC® 3D (Sirona) CAD-CAM i konvencionalna - Empress II (Ivoclar) tehnika.

Pacijent S.M. (36g., muški pol) se javio u ordinaciju zbog potrebe za protetskom sanacijom zuba 25. Pregledom je ustanovljen: gubitak vertikalne dimenzije krunice zuba 25, rekonstruisane neadekvatnim kompozitnim ispunom, elongacija vitalnog i intaktnog antagonističkog zuba, intaktni agonisti. Pri planiranju terapije, uzete su ove činjenice u obzir pa je odlučeno da se izradi bezmetalna endokruna. Obzirom da je dodatni zahtev pacijenta bila i brzina izrade, odabran je CAD/CAM postupak jednoseansne izrade.

CEREC®3D je ordinacijski CAD-CAM sistem, prvenstveno namenjen rekonstrukciji pojedinačnog zuba. Srce sistema predstavlja 3D intraoralna kamera, koja ima ulogu da prikupi sve relevantne podatke merenja preparisanog zuba i okolnih struktura. Dobijeni podaci se obrađuju pomoću softvera na kompjuteru i dobija se virtuelni model preparisanog zuba na kome se izrađuje virtuelna nadoknada. Završni postupak je frezovanje željenog oblika nadoknade iz odgovarajućeg bloka keramičkog materijala.

Specifičnosti preparacija korenskog dela zuba za CAD/CAM endokrunu je u sandučastom obliku kaviteta koji ne prelazi dubinu od 2-4 mm. Dno kaviteta se završava površinski. Kavitet može biti u jednom komadu ili podeljen u dva dela što ne zavisi samo od klase zuba, već prvenstveno od količine preostalog zdravog zubnog tkiva i oblika korenskog sistema. Osnovni zahtev je da su sve površine zidova i dna kaviteta vidljive iz jedne tačke (okluzalni pogled), odnosno da ne sme da bude podminiranih niti divergentnih delova kaviteta.

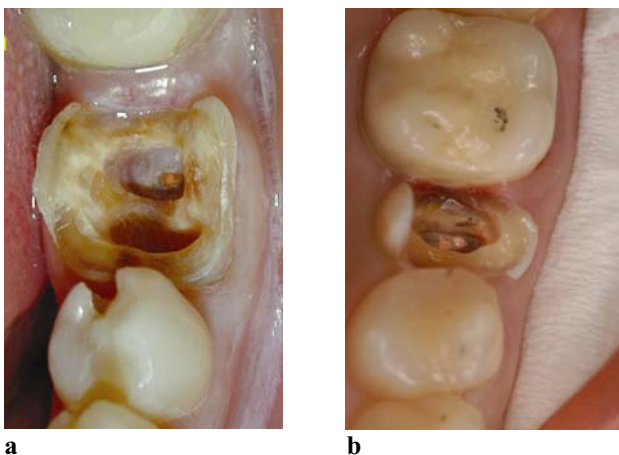
## Subjects and Methods

In the present paper, two techniques for the production of all-ceramic endo-crowns are presented with case reports: single-visit CEREC® 3D (Sirona) CAD-CAM and the conventional Empress II (Ivoclar) technique.

Patient S.M (36, male) visited the dental office in the need for prosthodontic restoration of tooth 25. Clinical examination revealed: the loss of vertical dimension of the crown (tooth 25), restored with an inadequate composite restoration, elongation of the vital and intact antagonist tooth, intact adjacent (agonist) teeth. During treatment-planning, these facts were taken into consideration and it was decided to produce an all-ceramic endo-crown. Due to the additional patient's request for a prompt restoration, the single-visit CAD-CAM approach was chosen.

CEREC® 3D is an in-office CAD-CAM system, primarily designed for single tooth reconstruction. The heart of the system is a 3D intraoral camera, designed to collect all relevant measurement data of the prepared tooth and adjacent structures. The data is analyzed using computer software to create a virtual model of the prepared tooth, which is, then, used to create a virtual restoration. The final stage is milling the ceramic block into a final restoration shape.

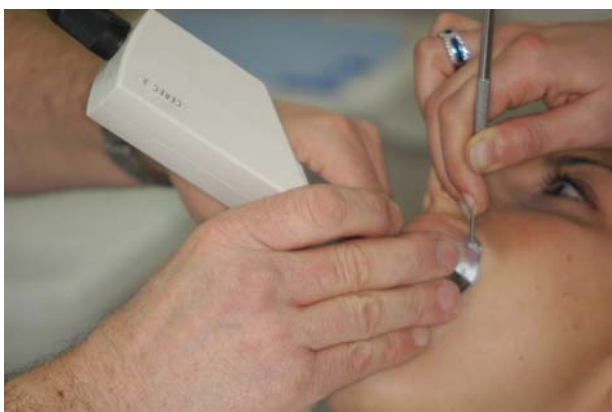The special characteristic of the root part of the preparation is a box-shaped cavity which does not exceed the depth of 2-4 mm. The bottom of the cavity is finished superficially. The cavity can be prepared as a single-unit cavity or divided into two parts which not only depends on the tooth morphology, but primarily on the amount of the remaining dental tissue and the root canal shape. The main requirement is that all surfaces (walls and cavity bottom) are visible from one point (occlusal view) i.e. no undermined or divergent parts of the cavity are allowed.



*Slika 1. Izgled preparisanog korenskog dela zuba za bezmetalnu endokrunu; a) podeljen i b) jednozapreminski.*

**Figure 1.** The root prepared for an all-ceramic endo-crown; a) divided and b) single chamber

“Otiskivanje“ preparacije vrši se intraoralnim optičkim 3D skenerom. Kompjuteru je potrebno nekoliko sekundi da podatke obradi i na ekranu prikaže virtuelni model preparisanog zuba sa agonistima. U narednoj fazi terapeut bira jednu od tri mogućnosti za dizajniranje nadoknade. Prva je mogućnost korišćenja biblioteke podataka samog softvera. Bira se gotov dizajn koji će najviše odgovarati pacijentu, prilagođen i doteran softverskim alatima prema anatomskim i funkcionalnim karakteristikama individue. Druga je tzv. korelacija, što podrazumeva skeniranje zuba pre bilo kakve intervencije, a zatim i skeniranje preparacije, kada se sintezom ove dve slike projektuje virtuelni dizajn buduće nadoknade. Treći način je replikacija, odnosno skeniranje istog zuba iz suprotnog kvadranta, i invertovanje slike kao lik u ogledalu na preparisan zub.



“Impression” is taken using the intraoral optical 3D scanner. The computer needs a couple of seconds to analyze data and present a virtual model of the prepared tooth with adjacent teeth (agonists). In the next stage, the clinician chooses one of three options to design the restoration. The first option is to use the computer’s database to select available design which will be altered by the software tools to match the anatomical and functional characteristics of the individual patient. The other is the so-called correlation, the tooth before the intervention and the preparation afterwards are scanned and the synthesis of the two images creates the virtual design of the future restoration. The third option is the replication, when the counterpart tooth is scanned and converted as the mirror image of the prepared tooth.

*Slika 2. Optičko „otiskivanje“ CEREC® 3D intraoralnim skenerom.*

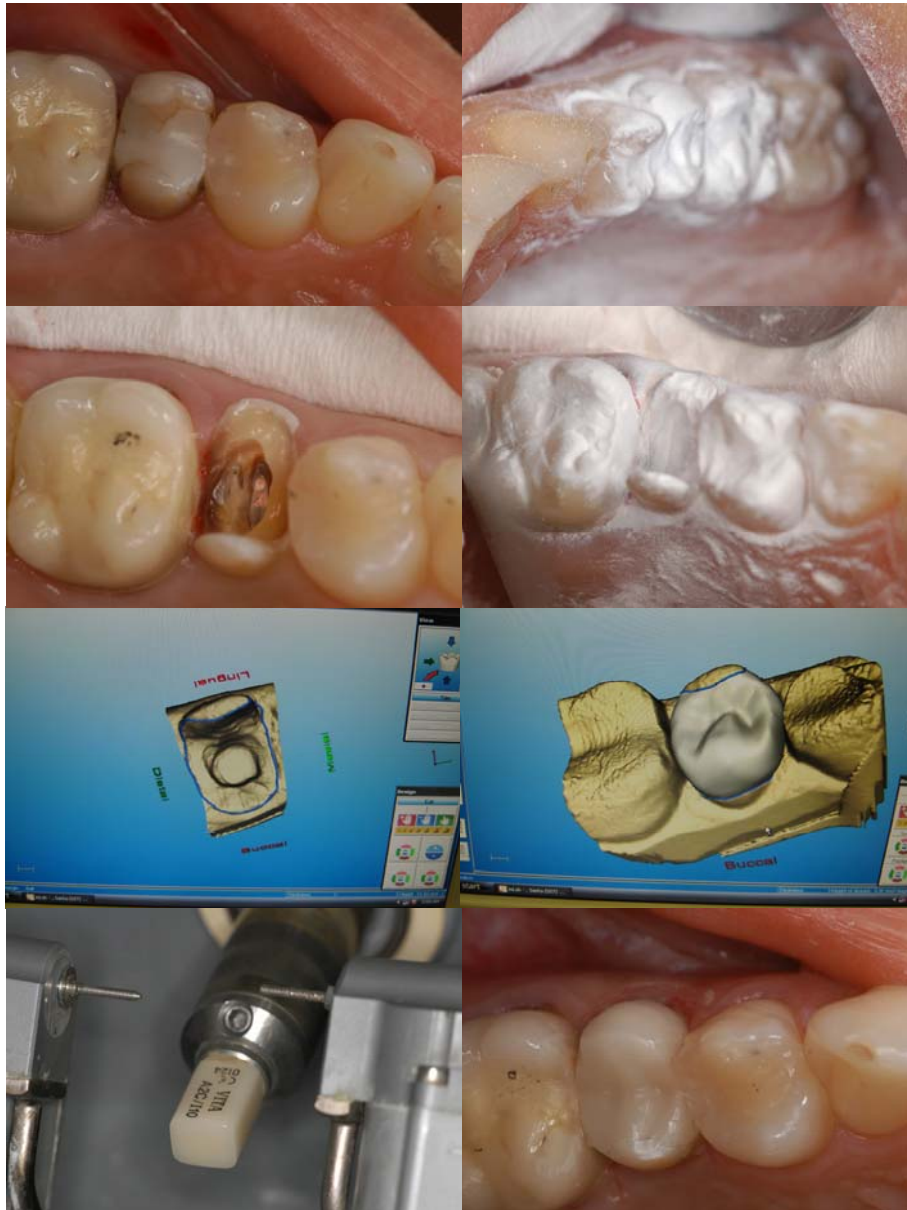*Figure 2. Optical “impression” using the Cerec 3D intra-oral scanner.*

Obzirom da je krunica zuba 25 pacijenta S.M. bila relativno očuvana (slika 3a), izabran je postupak korelacije za dizajniranje virtuelnog modela endokrone. U toj fazi dolazi do izražaja dobro poznavanje morfologije zuba i umeće rukovanja softverom CAD–CAM sistema CEREC® 3D. Naime, tada stomatolog dizajnira izgled buduće nadoknade softverskim alatima na virtuelnom modelu. Nakon postizanja željenog oblika krunice zuba u kompozitu, polje koje će se skenirati matira se prahom titanoksida (slika 3b). Na ovaj način se obavlja prvi skening. Dobijeni virtuelni model zuba 35 (slika 3c) se potom arhivira.

Tek tada se pristupa preparaciji zuba (slika 3d), nakon čega se ponavlja postupak skeniranja, ali sada preparisanog zuba (slika 3e). Softver tada započinje, već opisan, postupak korelacije.

Given the fact that the crown of tooth 25 was relatively well maintained the correlation procedure was chosen to design the virtual model of the endo-crown. At this stage, the knowledge of dental morphology and computer software is essential, as the dentist creates the design of the future restoration using software tools on the virtual model. When the desired crown shape is achieved in the composite, the area to be scanned is covered with titanium-oxide powder (Figure 3b). The first scan is taken. The obtained virtual model of the tooth 25 (Figure 3c) is then archived.

Only then can the tooth preparation be performed (Figure 3d), and the scanning procedure is repeated on the prepared tooth (Figure 3e). Computer software now starts the correlation procedure.



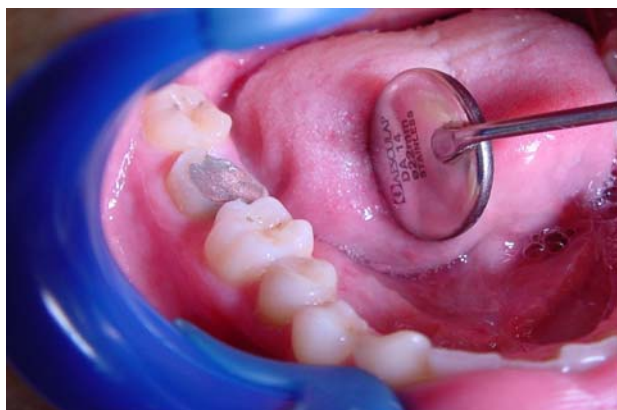*Slika 3. Jednoseansna izrada endokrone na zubu 25 CEREC® metodom: a) početno stanje, b) priprema za primarno skeniranje prahom titanoksida, c) preparacija korenskog dela, d) priprema za skeniranje preparisanog zuba, e) skeniran preparisan zub, f) virtuelni dizajn endokrone, g) keramički blok iz koga će se izfrezovati endokruna, h) završena obrada endokrone metodom poliranja.*

**Figure 3. Chair-side production of the endo-crown on tooth 25 using the CEREC method>**  
*a) initial phase b) preparation for primary scanning with titanium-oxide powder c) root canal preparation  
 d) preparation for scanning of the prepared tooth e) scanned and prepared tooth f) virtual design of the endo-crown g) ceramic block for  
 milling the endo-crown h) final restoration after polishing.*

Kada je stomatolog zadovoljan sa dizajnom endokrone (slika 3 f), kompjuter preračunava njen oblik (CAD) i vodi mašinu za brušenje (CAM), koja materijalizuje virtuelni model u realnu nadoknadu iz keramičkog bloka prethodno odabranog od strane lekara po sastavu, veličini i boji (slika 3g). Obrada zavisi od tačnosti postupka skeniranja, kao i načina digitalizacije<sup>10</sup>. Quaas i saradnici<sup>11</sup> kao i mnogi drugi autori potvrdili su u svojim studijama da je već postignuta visoka preciznost postupka digitalizacije. CAD-CAM sistem CEREC<sup>®</sup>3D omogućuje da se dodatnim skeniranjem okluzalnog registrata antagonista dizajniraju nadoknade u virtuelnom artikulatu. Završena nadoknada se proba u ustima i može se polirati do visokog sjaja (slika 3h), ili preglazirati i individualizirati pigmentima. Cementiranje endokrone je izvršeno adhezivnim postupkom, uz prethodnu pripremu nadoknade fluorovodoničnom kiselinom i silanom.

Kod drugog pacijenta, endokurna je urađena presovanjem keramike. Pacijent D.S. (24g., ženski pol) je imala potrebu za terapijom krunice zuba 46. Pregledom je ustanovljena neadekvatna okluzalna ravan usled gubitka vertikalne dimenzije krunice ovog zuba prethodno saniranog neadekvatnim amalgamskim ispunom, praćena elongacijom intaktnog antagonističkog zuba. Zubi agonisti su, takođe, bili vitalni i intaktni. U uslovima nedostatka prostora za izradu klasične livene nadogradnje ili nekog drugog vida korenske retencije, koja bi podržavala zubnu nadoknadu, uz zahtev da se ne preparišu antagonisti ili agonisti, odlučeno je da se izrade bezmetalne endokrone, konvencionalnom metodom – sistemom presujuće keramike.

Empress II sistem je razvijen od strane firme Ivoclar Vivadent (Schaan, Liechtenstein). Sam postupak presovanja podrazumijeva viskozno pečenje keramike na visokim temperaturama i kalupljenje istopljenog ingota u šupljinu nastalu potpunom eliminacijom istopljenog voska.



When the dentist is satisfied with the design of the endo-crown (Figure 3f), the computer calculates its shape (CAD) and guides the milling machine (CAM), which materializes the virtual model into the real restoration out of a ceramic block previously chosen by the dentist, according to its composition, size and colour (Figure 3g). The milling accuracy depends on the accuracy of scanning and digitalization.<sup>10</sup> Quaas et al.<sup>11</sup> as well as other authors, have confirmed high precision of the digitalization procedure. CAD-CAM CEREC<sup>®</sup> 3D enables restoration designing in a virtual articulator after an additional scan of the occlusal surfaces of antagonists. The final restoration is checked in the mouth and polished to high gloss (Figure 3h) or glazed and individualized using pigments. The cementing of the endo-crown is achieved through the adhesive approach after pre-treatment with hydrofluoric acid and silane.

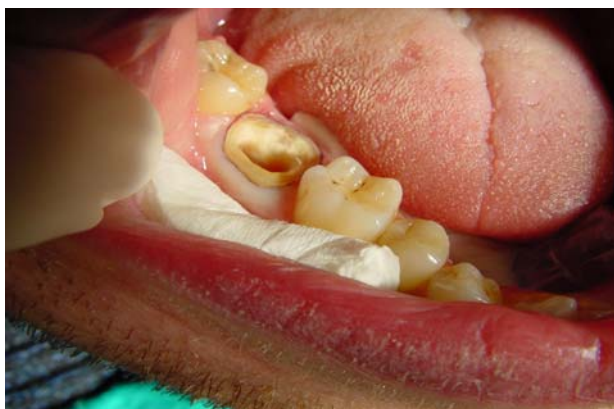In another patient, the endo-crown was produced using pressed ceramics. Patient D.S (24, female) needed a restoration on tooth 46. Clinical examination revealed inadequate occlusal plane due to the loss of vertical dimension of this tooth, which had been previously restored with an inadequate amalgam restoration, as well as the elongation of the intact antagonist tooth. The adjacent teeth (agonists) were also vital and intact. The decision to produce an all-ceramic endo-crown using the conventional pressed ceramics method was influenced by the lack of space for a cast core-build up or other form of root retention and the request to avoid the preparation of antagonists and agonists.

Empress II system was developed by Ivoclar Vivadent (Schaan, Liechtenstein). During fabrication, a mould is made of a wax-up of the restoration according to the lost-wax technique. An ingot is placed in the Empress furnace and pressed with an aluminium oxide plunger into a preheated muffle. High temperature is required to achieve the plasticity phase of the ceramic material necessary to ensure proper pressing and adaptation.

*Slika 4. Izgled zuba 46 prije restauracije*

*Figure 4. Tooth 46 before restoration*

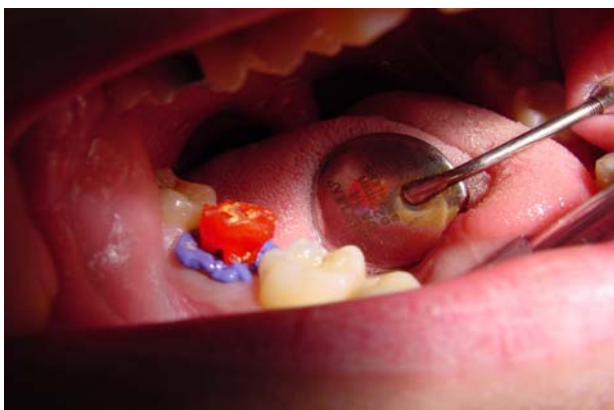Početno stanje je prikazano na slici 4, sa jasno vidljivom sniženom visinom krune zuba 46. Kanal korena je preparisan, kao za livenu nadogradnju, vodeći računa da se stvori dovoljno prostora za adekvatnu debljinu keramike. Demarkacija preparacije je locirana supragingivalno. Otisak se uzima adicisionim silikonima, uz pomoć preoblikovane akrilatne nadogradnje. Ova nadogradnja je specifična po tome, što je između nje i zidova kanala zuba postoji prostor za ređu otisnu masu., dobijen skidanjem sloja akrilata. Adicioni silikon se u kanal korena aplikuje špricom nakon čega se postavlja pripremljena akrilatna nadogradnja i preko nje uzima otisak.



The initial phase is presented in Figure 4, the reduced crown height of tooth 46 is clearly visible. The root canal is prepared as for a cast build-up and care is taken to ensure sufficient space for adequate thickness of ceramics. The preparation margin is located supragingivally. The impression is taken using addition silicones and an adjusted acrylic build-up. This build-up is specially designed by removing a layer of acrylic to create space between the build-up and canal walls for the low-viscous impression material. Addition silicone is injected into the root canal using a syringe; the acrylic build-up is fitted in place and the impression taken.

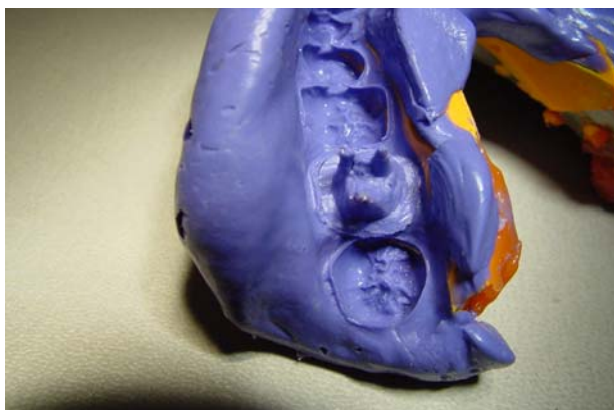
*Slika 5. Priprema kaviteta za uzimanje otiska*

*Figure 5. Cavity preparation for impression*



*Slika 6. Uzimanje otiska za endokrunu*

*Figure 6. Taking an impression*



*Slika 7. Otisak A silikonima za endokrunu*

*Figure 7. A silicone impression for endo-crown*



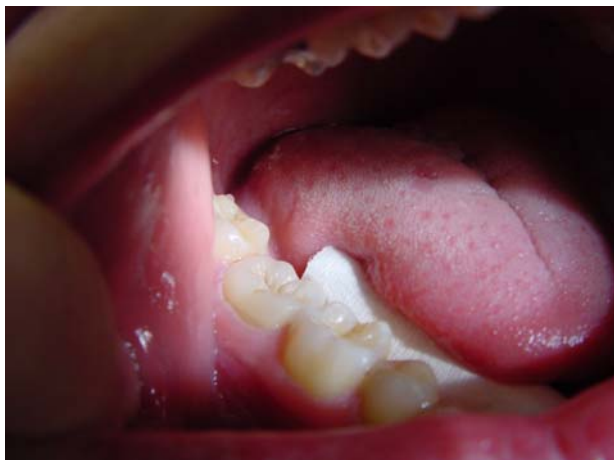Svrha akrilatne nadogradnje je da spreči deformaciju otiska. Prilikom uzimanja otiska, potrebno je izbeći direktan kontakt akrilatne nadogradnje i zida kanala korena, jer prilikom izlivanja otiska može doći, bez obzira na upotrebu izolacionog sredstva, do slepljivanja akrilata i gipsa, čime će biti onemogućeno odvajanje nadogradnje od otiska.

Tehnički deo izrade se sprovodi po klasičnoj proceduri presovanja koja podrazumeva modelovanje nadogradnje u vosku, ulaganje, žarenje, presovanje i definitivnu obradu nadoknade.

Nakon provere naleganja na modelu, nadoknada se može individualno karakterisati bojama za keramiku, nakon čega se kruna glazira<sup>12</sup>. Opisani postupak odgovara tzv. Staining pres tehnici, koja se preporučuje za izradu nadoknada koje trpe veća funkcionalna opterećenja<sup>13</sup>.

Gotova nadoknada se adhezivno cementira upotrebom odgovarajućih dvojno vezujućih komponenti cementa što je neophodno kod cementiranja endokrone, zbog velike debljine keramike nadoknade i zubnog tkiva, kroz koje ne može da prođe polimerizujuća svetlost.

Uklanjanje viška cementa, olakšano je supragingivalnom lokalizacijom demarkacije preparacije. Završni izgled nadoknade prikazan je na slici 8.



The aim of the acrylic build-up is to prevent impression deformation. During the impression procedure, it is important to avoid the direct contact between the acrylic build-up and canal walls as acrylic may come into contact with gypsum during casting and prevent separation of the build-up from the cast.

The technical part of the fabrication is performed according to the conventional procedure of ceramic pressing and included designing the build-up in wax, casting, heating, pressing and finishing.

After the restoration is checked on the model, it may be characterized individually using pigments for ceramics, and afterwards the crown is glazed.<sup>12</sup> The described procedure is also known as the staining press technique, recommended for restorations which will be subjected to increased functional load.<sup>13</sup>

The finished restoration is cemented using dual-cure adhesive cements and this is necessary due to the thickness of ceramics and dental tissues which prevent the polymerisation light.

The removal of excess material is easy as the preparation margin is located supragingivally. The final restoration is presented in figure 8.

*Slika 8. Izgled definitivne nadoknade*

*Figure 8. Final restoration*

## Diskusija

Primena endokrone u terapiji endodontski lečenih zuba je, u novije vreme, tema brojnih istraživanja. Obzirom na oblik, veličinu korenskog dela i gradivni materijal, osnovni nedostatak endo kruna bi trebao biti problem rascementiravanja i fraktura. Praksa, prema literaturnim podacima, pokazuje suprotno.

Na kontrolnim pregledima, 12 meseci nakon izrade endokrone Cerec i Empres metodom, kod prethodno opisanih slučajeva, nije utvrđena nikakva estetska ili funkcionalna degradacija nadoknade.

## Discussion

The use of endo-crowns in the reconstruction of endodontically treated teeth has recently become the subject of numerous studies. The main disadvantage of endo-crowns should be debonding and fracture regarding the shape and size of the root canal part and the material. However, clinical practice, according to literature data, shows the opposite.

At follow-ups 12 months after the cementation of Cerec and Empress endo-crowns in previously described patients, no aesthetic and functional degradation was noticed.

Veza nadoknade i zuba je bila bez vidljivih oštećenja i diskoloracija. Ovi nalazi su saglasni sa rezultatima naših ranijih ispitivanja<sup>14</sup> koja su pokazala da od 34 Cerec endokrone, izrađene u dvogodišnjem periodu ni u jednom slučaju nije došlo do rascementiranja, niti pucanja korenskog dela nadoknade. Kod jedne endokrone je došlo do oštećenja kruničnog dela keramike.

Do sličnih rezultata su došli Bindl i Mormann<sup>15</sup>, u kliničkoj studiji sa adhezivno cementiranim Cerec endokrunama. Kontrolisano je 19 nadoknada (4 premolara i 15 molara), kod 13 pacijenata u periodu od 28 meseci. Samo je jedna nadoknada na molaru bila oštećena zbog pojave sekundarnog karijesa, dok kod ostalih nisu utvrđene nikakve promene. Kod 79 endokruna izrađenih Empress II tehnikom u periodu od 2 godine Toksavul i Toman<sup>16</sup> su utvrdili frakturu samo na jednoj nadoknadi zuba. Stanje preostalih ispitanih nadoknada je ocenjeno kao zadovoljavajuće.

Teoretsku potporu ovakvoj vrsti nadoknada dali su Zarone i sar.<sup>17</sup>, koji su studijom obuhvatili nekoliko vrsta fiksnih nadoknada izrađenih od različitih materijala na maksilarnim sekutićima. Ispitivanje je rađeno analizom 3D konačnih elemenata i utvrđeno je da su kritična polja visokog stresa, kod klasičnih nadoknada na endodontski lečenim zubima, skoncentrisana u polju nadoknada- cement – dentin.

Primenom jednokomadnih nadoknada, kao što je endokruna, postiže se redukcija veznih površina na najmanju moguću mjeru, čime se automatski redukuju i zone najvećeg stresa, i povećava otpornost nadoknade na pucanje ili rascementiranje.

Pozitivni klinički rezultati se mogu objasniti adhezivnim cementiranjem, koje nadoknađuje redukovanu dužinu korenskog dela nadoknade<sup>18</sup>, i manjim krakom poluge od uobičajenog koji deluje na ovakav tip nadoknade. Za endokrunu izrađenu Empress tehnikom, korenski deo krunice može biti nešto duži u odnosu na Cerec nadoknadu, kod koje postoji ograničena mogućnost optičkog otiskivanja dubine korenskog kaviteta. Ispitivanja su pokazala da ne postoji značajna razlika u incidenciji rascementiranja između endokruna izrađenih CAD-CAM tehnikom<sup>19</sup> i Empress II tehnikom<sup>16</sup>.

Empres sistem poseduje već dokazane vrednosti, ali obzirom da se radi o ručno rađenim nadoknadama, kvalitet i funkcionalnost individualno varira u zavisnosti od ljudskog faktora (umešnosti, trenutne inspiracije ili tehničkih mogućnosti zubnog tehničara), osobina materijala, procedura itd. S druge strane, kompjuterska modelacija, ma kako izgledala automatizovana, takođe je podložna ljudskoj grešci, ali je ona ipak svedena na minimum.

Drugi aspekt funkcionalnosti vezan je, za gradivni materijal od koga se nadoknada izrađuje. Konvencionalna izrada endokruna može koristiti samo lusitom ojačanu keramiku, dok Cerec sistem koristi širu paletu materijala (feldspatnu, lusitnu keramiku ali i kompozitne materijale)<sup>20</sup>.

The restoration-tooth bond did not show any signs of damage or discoloration. These results are in agreement with previous studies<sup>14</sup> which showed neither debonding nor root fracture in 34 endo-crowns over a 2-year period. In one endo-crown, ceramic was damaged.

Similar results were reported by Bindl and Mormann<sup>15</sup> in a clinical study of Cerec endo-crowns, cemented adhesively. Nineteen restorations were checked (4 premolars and 15 molars) in 13 patients over 28 months. Only one molar restoration was fractured due to secondary caries and no changes were observed in other restorations. In 79 endo-crowns fabricated using the Empress II technique, Toksavul and Toman<sup>16</sup> reported only one fracture over a 2-year period. The status of other endo-crowns was found to be satisfactory.

A theoretical support for this type of restorations was offered by Zarone et al.<sup>17</sup> who studied several types of fixed restorations from different materials on maxillary incisors. Their 3D finite element analysis showed that critical areas of high stress in conventional restorations on endodontically treated teeth were located in the restoration-cement-dentine zone.

Single-unit restorations, such as endo-crowns, reduce bonded surfaces as well as high stress zones and increase fracture or debonding resistance.

Favourable clinical results may be explained with adhesive cementing which compensates the reduced length of the root part due to the reduced than usual fulcrum side. In Empress endo-crowns, the root part may be slightly longer than in Cerec restorations due to the limited ability of optical impression of the canal preparation in the latter. Studies have shown no difference in the incidence of debonding between CAD-CAM<sup>19</sup> and Empres II<sup>16</sup> endo-crowns.

The Empress system has certain advantages but the quality and functionality may vary individually due to material properties, procedures etc. but also the fact that these are hand-made restorations (skill, inspiration, technical factors). On the other hand, computer modelling, no matter how automated may seem, is also prone to human error although this is reduced to minimum.

Another aspect of functionality is associated with the material which the restoration is made of. The conventional technique of endo-crown fabrication may use only leucite-reinforced ceramics, whilst the Cerec system uses a wider range of materials (feldspar, leucite ceramics but also composite materials).<sup>20</sup>

Estetski aspekti poređenja zavise od nadahnuća i umešnosti stomatologa i zubnog tehničara. Presujući sistemi zasigurno mogu obezbediti punu individualizaciju, no ona bi tada podrazumevala upotrebu lejering tehnike, što se, iz razloga mehaničke otpornosti, kod endokrone ne preporučuje. Iz tog razloga kod oba sistema se definitivna boja, najčešće, dobija postupkom glaziranja. Staining tehnika, s obzirom da se radi o bočnoj regiji, pruža sasvim zadovoljavajuće rezultate, iako su pigmenti površinski, bez dubinskih efekata. CAD/CAM nadoknade, bez individualne pigmentacije, koja podrazumeva primenu keramičke peći u ordinaciji, teško da se mogu porediti sa estetikom tehnički obrađenih i glaziranih nadoknada, čak i ako se koriste trilux blokovi. Međutim, ukoliko je ordinacija, pored samog Cerec sistema, opremljena i sa peći za sinterovanje keramike, onda ovakve nadoknade mogu pokazati jednak nivo estetike kao i presujuće nadoknade, te se, samo na osnovu ovog kriterijuma, od njih ne mogu razlikovati.

Dužina trajanja procedure svakako ide u prilog CAD/CAM sistemima. Jednosedno urađena nadoknada, sigurno je u velikoj prednosti u odnosu na klasičan postupak modelacije, koji podrazumeva vreme potrebno za transport otiska, izlivanje modela, izradu voštanog modela, presovanje keramike i obradu same nadoknade.

Obe tehnike izrade nadokada imaju određene prednosti, ali zajednički problem predstavlja prisustvo keramike u korenskom kanalu, što limitira upotrebu endokrone kod pacijenata sa očuvanom vertikalnom dimenzijom okluzije. Razlika u modulu elastičnosti keramičkih materijala i dentina zuba, nosi rizik za nastanak frakture kanala korena. Razvoj kompozitnih blokova za CAD-CAM tehniku predstavlja jedan od mogućih puteva za razrešenje ovih problema.

## Zaključak

Izrada keramičkih endokrona je metoda izbora kod endodontski lečenih zuba sa smanjenom vertikalnom dimenzijom okluzije, ukoliko postoji dovoljno zdrave zubne supstance, prvenstveno gleđi. Ovakve nadoknade zadovoljavaju sve funkcionalne i estetske zahteve.

Osnovnu prednost endokrona izrađenih metodom presovanja predstavlja veća dubina korenskog dela nadoknade i postupak izrade koji omogućuje konvencionalnu kontrolu nadoknade u artikulatu. Ipak, jednosedna izrada i veća paleta gradivnih materijala, koji se mogu koristiti za njihovu izradu, predstavljaju prednost Cerec CAD - CAM tehnologije.

Aesthetic aspects of comparison depend on the inspiration and skill of the dentist and technician. The pressing system provides full individualization but in that case requires the layering technique which is not recommended in endo-crowns due to mechanical reasons. For this reason, the final colour in both systems is achieved during glazing. In the posterior region, the staining technique provides satisfactory results, although pigments are superficial with no deep effects. CAD-CAM restorations without individual pigmentation can hardly be compared to finished and glazed restorations even when trilux blocks are used. However, if the dental office has the ceramic sintering furnace along with the Cerec system, then these restorations may be equally aesthetic as pressed restorations and cannot be distinguished from them using this single criterion.

The duration of the procedure is in favour of the CAD-CAM systems. The restoration produced in a single-visit has a great advantage over the conventional procedure which includes impression transport, casting, wax modelling, pressing ceramic and finishing the restoration.

Both techniques have certain advantages but the mutual problem is the presence of ceramic in the root canal, limiting the use of endo-crowns in patients with normal occlusal vertical dimension. The difference in modulus of elasticity between ceramic and dentine poses risk of root fracture. The development of composite blocks for the CAD-CAM technique is one of possible ways to solve this problem.

## Conclusion

All-ceramic endo-crowns are a method of choice in endodontically treated teeth with reduced occlusal vertical dimension and sufficient tooth substance, especially enamel. These restorations conform to all functional and aesthetic requirements.

The main advantage of endo-crowns fabricated using the pressing method is the greater depth of the root part and the procedure itself, which allows conventional control of the restoration in an articulator. However, single-visit approach and a wider range of materials are advantages of the CAD-CAM technology.

## Literatura / References

1. *Asmussen E, Peutzfeldt A, Sahafi A.* Finite element analysis of stresses in endodontically treated, dowel-restored teeth. *J Prosthet Dent* 2005; 94: 321-9.
2. *Sirimai S, Riis DN, Morgano SM.* An in vitro study of the fracture resistance and the incidence of vertical root fracture of pulpless teeth restored with six post-and-core systems. *J Prosthet Dent* 1999; 8: 262-9.
3. *Bergman B, Lundquist P, Sjogren U, Sundquist G.* Restorative and endodontic results after treatment with cast post and cores. *J Prosthet Dent* 1989; 61: 10 – 15
4. *Sorensen JA, Engleman MJ.* Effect of post adaptation on fracture resistance of endodontically treated teeth. *J Prosthet Dent* 1990; 64: 419 – 424
5. *Testori T, Bandino M, Castagnola M.* Vertical root fractures in endodontically treated teeth : a clinical survey of 36 cases. *J Endod* 1993; 19: 87 – 91
6. *Asmussen E, Peutzfeldt A, Hetmann T.* Stiffness, elastic limit, and strenght of newer types of endodontic post. *J Dent* 1999; 27: 275 – 278
7. *Akkayan B, Gulmez T.* Resistance to fracture of endodontically treated teeth restored with different post systems. *J Prosthet Dent* 2002; 87: 431 – 437
8. *Vuličević Z, Todorović A, Anđelković S, Mandić N.* Mogućnost nadogradnje devitalizovanih zuba kompozitima ojačanim staklenim vlaknima – prikaz slučaja. VII Simpozijum protetičara Srbije, Zlatibor 2000
9. *Shillingburg TH, et.al.* Fundamentals of fixed prosthodontics- third edition, Chicago: Quintessence publishing Co, Inc, 1997: pp194.
10. *Luthardt R, Kuhmstedt P, Schimpf K.* Methodische genauigkeit der kliniscen analyse von formabweichungen beim einsatz von digitalisierverfahren. *Dtsch Zahnarzl.* 2003; 58: 538 – 542
11. *Quaas S, Sporbeck H, Luthardt R. G.* Analyse der digitalisiergenau von gesamtmodellen bei mehrfachmessung. *Dtsch Zahnarzl* 2003; 58: 543 -545
12. *Hata U, Sadamitsu K, Yamamura O, Kawauchi D, Fujii T.* Chromatic study of all ceramic crown – IPS Empress: difference of color by manufacturing technique and cements. *Journal of the Japan Prosthodontic Society* 2004; 48: 703 – 712
13. *Hata U.* A case of restoring using IPS Empress (staining technique) for upper central incisors. *Journal of the Japan Prosthodontic Society* 2007; 51: 592 – 595
14. *Lazić V, Todorović A, Veselinović V, Lisjak D.* Bezmetalne endokrone, II Kongres Stomatologa Bosne i Hercegovine, *Abstrakt Book*, Teslić, 2007
15. *Bindl A, Morman WH.* Clinical evaluation of adhesively placed Cerec endocrown after 2 years – preliminary results. *Journal of adhesive dentistry* 1999; 22: 255 – 265
16. *Toksavul S, Toman M.* A short-term clinical evaluation of IPS empress 2 crowns. *International Journal of Prosthodontics* 2007; 20:168 – 172
17. *Zarone F, Sorrentino R, Apicella D, et. al.* Evaluation of the biomechanical behavior of maksillary central incisors restored by means of endocrown compared to natural tooth: A 3D static linear finite elements analysis. *Dental material* 2006; 22: 1035 – 1044
18. *Kerstin B, Andrej M, Kielbassa M.* Dentinski adhezijski sistemi u korjenskom kanalu. *Quintessence international* 2005; 9: 749 – 758
19. *Otto T:* Computer- aided direct all ceramic crowns: preliminary 1-years results of prospective clinical study. *Int J Periodont Restorative dent* 2004; 25: 446 – 455
20. *Filser F, Kocher P, Weibel F, Luthy H, Scharer P, Gauckler LJ:* Reliability and strenght of all-ceramic dental restauration fabricatec by direct ceramic maschinig (DCM). *Int J Comp Dent* 2001; 4: 89 – 106

### Adresa za korespondenciju

Todorović Aleksandar  
Rankeova 4, Beograd  
063-212174  
Acatodor@eunet.yu

### Address for correspondence

Todorović Aleksandar  
Rankeova 4, Belgrade  
063-212174  
Acatodor@eunet.yu